

CASE REPORT

The Battle Within: Command Hallucinations Driving Recurrent Urethral Foreign Body Insertion in Schizophrenia – A Case Report

Sherwin Chester R. Tape, MD, Christine Joy G. Castillo, MD, DPBU, FPUA
Aristotle Bernard M. Roque, MD, FPUA, and Ceasar Ballesteros, MD, FPUA

Department of Urology, Jose R. Reyes Memorial Medical Center, Manila, Philippines

Objectives: To present a rare case of recurrent urethral and intravesical foreign body insertion driven by command hallucinations in schizophrenia, to describe the surgical and psychiatric management strategies employed, and to emphasize the importance of interdisciplinary care and treatment adherence in preventing recurrence.

Methods: Reported here is the case of a 37-year-old male with schizophrenia who presented with multiple episodes of urethral and intravesical foreign body insertion over a six-year period (2018–2025). Inserted objects included metallic wires, electrical cords, and a LED Christmas light rope, each requiring surgical removal via cystoscopy or open cystotomy. Psychiatric evaluation revealed poor adherence to antipsychotic medication, with recurrent episodes associated with command hallucinations. Psychiatric management was reinitiated with olanzapine and structured follow-up to improve treatment compliance.

Results: Six documented episodes of self-inflicted urethral and intravesical trauma required repeated urologic interventions. Despite recurrent instrumentation and foreign body insertion, serial cystoscopic evaluations demonstrated preserved urethral and bladder integrity without evidence of stricture formation. The most recent episode required open cystotomy for removal of a coiled LED light rope, which was successfully extracted without complications. Following coordinated psychiatric management and improved adherence to antipsychotic therapy, the patient remained asymptomatic and free of recurrence at three months follow-up.

Conclusion: This case highlights the unusual preservation of urethral integrity despite recurrent traumatic self-insertion. Effective management requires sustained psychiatric stabilization, multidisciplinary collaboration, and strict treatment adherence. Integration of psychiatric and urologic care is essential to prevent recurrence and improve long-term outcomes in patients with schizophrenia-related self-inflicted genitourinary injury.

Key words: Urethral foreign bodies, schizophrenia, cystoscopy, self-injurious behavior, psychotic disorders

Introduction

Foreign body insertion into the urethra is an uncommon but clinically significant urologic presentation. Its true incidence is difficult to

determine due to underreporting, but available literature confirms that it remains rare in the general population.^{1,2} Motivations for urethral foreign body insertion are varied and include autoerotic practices, sexual curiosity, intoxication,

and psychiatric disorders.¹⁻³ Among psychiatric conditions, schizophrenia is particularly important because command hallucinations may drive repetitive self-injurious behaviors, including the insertion of objects into the urinary tract.^{4,5} Patients frequently delay seeking medical attention because of embarrassment or social stigma, increasing the risk of complications such as urinary tract infection, urethral trauma, urinary extravasation, and urethral stricture formation.^{1,3,6}

Several reports have described the clinical presentation, diagnostic approach, and management of urethral foreign bodies. Diagnosis typically relies on a thorough history and physical examination, supported by imaging modalities such as plain radiography, ultrasonography, or computed tomography to identify and localize the foreign object.^{6,7} Most cases can be managed with minimally invasive endoscopic techniques, while open surgical procedures are reserved for complicated cases or failed endoscopic retrieval.^{1,2,8} However, the literature primarily focuses on single-episode cases, and limited data exist regarding recurrent foreign body insertion associated with psychiatric illness. Furthermore, standardized management protocols addressing the psychiatric component and strategies to prevent recurrence remain insufficiently described.

This report aimed to present a rare case of recurrent urethral and intravesical foreign body insertion in a patient with schizophrenia driven by command hallucinations. Despite multiple episodes and repeated urologic interventions, the patient maintained preserved urethral integrity, an uncommon finding in the context of recurrent trauma. This case highlights the importance of multidisciplinary collaboration between urologists and psychiatrists in managing psychiatric-driven genitourinary self-injury and preventing recurrence.

The Case

Patient Information

A 37-year-old male with a history of schizophrenia presented to the emergency department with suprapubic pain and dysuria for two days. He reported inserting a flexible LED Christmas light rope into his urethra, prompted

by command auditory hallucinations instructing him to expel a perceived urinary tract “stone.” The patient believed the object would aid stone removal and described temporary relief and satisfaction after insertion. His psychiatric history included multiple prior episodes of self-inflicted urethral foreign body insertion in 2019, 2023, and 2024, all requiring surgical removal. He had a documented history of noncompliance with olanzapine, poor psychiatric follow-up, and limited family supervision. Socially, he was unemployed with minimal social engagement, and there was no family history of psychiatric illness.

Clinical Findings

On examination, the patient was alert, oriented, and in no acute distress. Abdominal examination revealed suprapubic tenderness without bladder distension. External genitalia appeared normal, and no foreign body was visible at the urethral meatus. Other systemic examinations were unremarkable.

Diagnostic Assessment

Kidney-Ureter-Bladder (KUB) radiography revealed radiopaque, coiled metallic densities within the pelvic region, consistent with an intravesical foreign body (Figure 1). Urinalysis demonstrated microscopic hematuria. Cystoscopic evaluation showed no urethral masses or strictures; however, multiple false tracts along the urethra were noted, indicative of prior trauma. The bladder mucosa appeared intact, with both ureteral orifices clearly visualized. A coiled metallic foreign body was observed near the bladder neck (Figure 2).

Therapeutic Intervention

Initial endoscopic retrieval was unsuccessful due to the object’s size and configuration. The patient underwent open cystotomy via a Pfannenstiel incision approximately 2 cm above the pubic symphysis. Dense adhesions were encountered intraoperatively. The bladder was opened, revealing a coiled LED light rope, which was extracted intact without mucosal injury. The bladder was closed in two layers with absorbable sutures, and the abdominal wall was closed

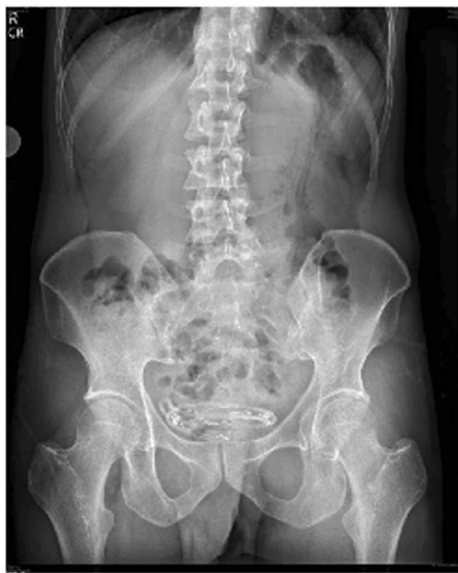

Figure 1. KUB X-ray showing radiopaque, coiled metallic densities consistent with intravesical foreign bodies in the pelvic region (2025).

routinely. A Foley catheter was left in place for two weeks. Postoperative care included oral antibiotics and resumption of olanzapine under behavioral medicine supervision.

Previous surgeries included:

- 2019: Urethrosopic and cystolithotomy removal of an ovoid radiopaque object
- 2023: Cystoscopic extraction of a knotted TV Plus cord
- 2024: Cystoscopic removal of an electric wire
- 2025 (current): Open cystotomy for the LED Christmas light rope (Figure 3)

Earlier procedures in 2018 and 2020 also documented similar foreign body removals, confirming a longstanding pattern of recurrent self-insertion.

Follow-up and Outcomes

Cystoscopic monitoring throughout multiple episodes revealed no urethral strictures. At the most recent follow-up, the patient reported no urinary symptoms and demonstrated improved adherence to psychiatric medications. He attended outpatient appointments regularly and engaged in recreational activities such as bicycling. These combined factors were considered critical in reducing the risk of recurrence and optimizing long-term recovery.

Ethical Considerations

Written informed consent for publication of this case report and accompanying images was obtained from the patient's legally authorized representative (his mother), as the patient was not competent to provide consent. This case report was conducted in accordance with the Declaration of Helsinki.

Discussion

Recurrent self-inflicted urethral and intravesical foreign bodies are uncommon and often linked to psychiatric disorders, particularly schizophrenia. Our case illustrates how psychosis, poor medication adherence, and limited social support contribute to repeated genitourinary self-injury, emphasizing the interplay between psychiatric illness and urologic complications.

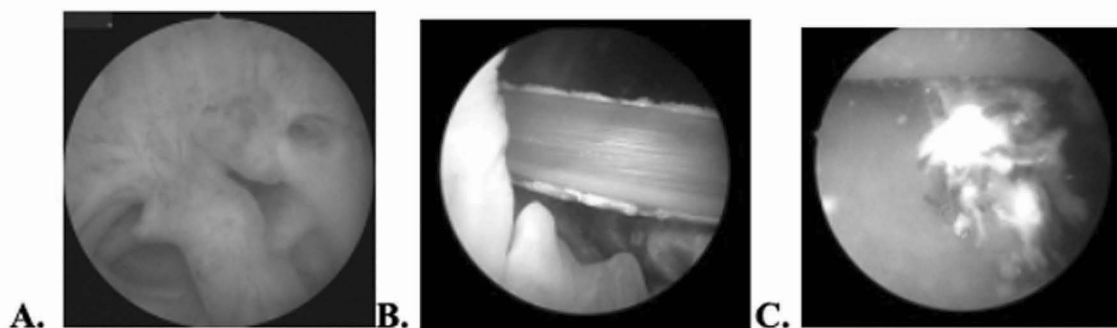


Figure 2. Cystoscopy findings: A. Multiple false tracts in urethra (2025), B. Foreign body (cable wire) near bladder neck (2024), C. Tip of foreign body (knotted wire) (2024).

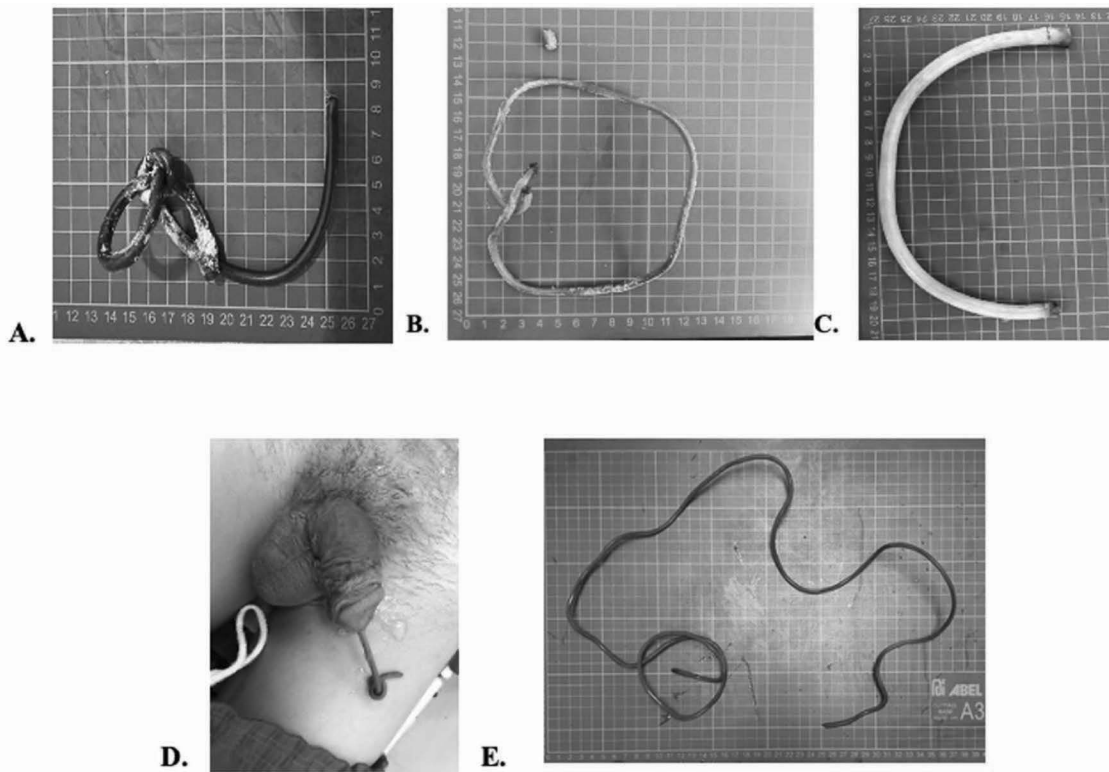


Figure 3. Extracted foreign bodies over multiple years: A. Knotted TV Plus cord (2023), B. Electric wire (2024), C. Flexible LED Christmas light rope (2025), D. Preoperative image of the foreign body inserted in the urethra-insulated wire (2020), E. Actual specimen of the foreign body removed-insulated wire (2020).

From a urological standpoint, repeated insertion of rigid objects increases the risk of chronic inflammation, urethral strictures, bladder injury, and upper urinary tract compromise. Interestingly, despite multiple traumatic insertions in our patient, no urethral strictures or bladder fibrosis developed, suggesting possible individual anatomical resilience and highlighting the need for tailored follow-up. Imaging for localization and characterization remains essential, while endoscopic retrieval is preferred, reserving open surgery for complex cases.

Psychiatric management is critical in preventing recurrence. Sustained antipsychotic therapy, psychoeducation, behavioral interventions, and caregiver involvement improve adherence and reduce relapse risk. Coordinated multidisciplinary care is essential, as surgical management alone rarely prevents recurrence.

Current APA and NICE guidelines advocate individualized risk assessments, long-term

psychiatric follow-up, and interdisciplinary collaboration.^{9,10} However, formal urological protocols for self-inflicted genitourinary foreign bodies remain lacking, particularly in recurrent cases. In the Philippine context, financial constraints, limited access to long-acting antipsychotics, and insufficient specialized psychotherapy pose additional challenges, underscoring the need for locally adapted integrated care pathways.

This case contributes novel insight by demonstrating preserved urethral and bladder integrity despite repeated traumatic insertions, contrasting with typical reports of high stricture incidence. Current findings reinforce the importance of psychiatric-centered care and individualized surveillance to minimize recurrence and long-term morbidity in this vulnerable population. Future research should focus on standardized management guidelines and preventive strategies integrating urology and psychiatry.

Conclusion

In this case of recurrent self-inflicted urethral foreign bodies in a patient with schizophrenia, surgical removal effectively managed the acute urological injury, while psychiatric noncompliance contributed to repeated episodes. Despite multiple traumatic insertions, no urethral stricture or bladder fibrosis developed, suggesting individual anatomical resilience. These findings support the importance of coordinated urologic and psychiatric care, emphasizing adherence to antipsychotic therapy, psychoeducation, and caregiver involvement to reduce recurrence.

References

1. Palmer CJ, Houlihan S, Psutka SP, et al. Urethral foreign bodies: clinical presentation and management. *Urology* [Internet] 2016 May [cited 2026 Mar 10];97:257-60. Available from: <http://dx.doi.org/10.1016/j.urology.2016.07.034>
2. Van Ophoven A, deKernion JB. Clinical management of foreign bodies of the genitourinary tract. *J Urol* [Internet]. 2000 Feb [cited 2026 Mar 10];164(2):274-87. Available from: [http://dx.doi.org/10.1016/S0022-5347\(05\)67342-9](http://dx.doi.org/10.1016/S0022-5347(05)67342-9)
3. Sukkarieh T, Smaldone M, Shah B. Multiple foreign bodies in the anterior and posterior urethra. *Int Braz J Urol* [Internet]. 2004 [cited 2026 Mar 10];30(3):219-20. Available from: <https://doi.org/10.1590/S1677-55382004000300010>
4. Rafique M. Intravesical foreign bodies: review and current management strategies. *Urol J* [Internet]. 2008 [cited 2026 Mar 10];5(4):223-31. Available from: <https://www.urologyjournal.org/article/5/4/223>
5. Amiroune D, Bouhadoun S, Keddari H, et al. Retained self-inserted foreign body into the urethra: a case report and review of the literature. *J Med Case Rep* [Internet]. 2014 [cited 2026 Mar 10];8:244. Available from: <http://dx.doi.org/10.1186/1752-1947-8-244>
6. Trivedi R, Kankaria A, Aggarwal R, et al. Management of neglected urethral foreign bodies with strictures: a case series. *Urol Case Rep* [Internet]. 2025 [cited 2026 Mar 10];54:102834. Available from: <http://dx.doi.org/10.1016/j.eucr.2025.102834>
7. Lumen N, van Compernelle F, Verhaeghe W, Hoebeke P, Spinoit AF. Endoscopic removal of self-inflicted urethral foreign body: a case report. *Urol Case Rep* [Internet]. 2022 [cited 2026 Mar 10];43:102140. Available from: <http://dx.doi.org/10.1016/j.eucr.2022.102140>
8. Ali A, Muhammad A, Fiaz M, et al. Urethral foreign bodies: clinical presentation and management. *Afr J Urol* [Internet]. 2021 [cited 2026 Mar 10];27:24. Available from: <http://dx.doi.org/10.1186/s12301-021-00180-8>
9. National Institute for Health and Care Excellence. Psychosis and schizophrenia in adults: prevention and management. NICE Clinical Guideline CG178 [Internet]. 2014 [cited 2026 Mar 10]. Available from: <https://www.nice.org.uk/guidance/cg178>
10. American Psychiatric Association. Practice guideline for the treatment of patients with schizophrenia. 3rd ed. Washington, DC: American Psychiatric Publishing; 2020. p. 868-72.