

## CASE REPORT

# Transvesical Subtrigonal Buccal Mucosa Graft Inlay for an Almost Completely Obliterated Bladder Neck Contracture: A First in the Philippines

Krizel Marie C. Faustino, MD<sup>1</sup>, Cholson Banjo Garcia, MD, FPUA, Dony Santiago, MD, FPUA<sup>1</sup>, Ambrichirus T. Lacanilao, MD, FPUA<sup>1</sup>, Oyayi Arellano, MD, FPUA<sup>2</sup> and Mark Joseph J. Abalajon, MD, FPUA<sup>2</sup>

<sup>1</sup>*Section of Urology, Dr. Paulino J. Garcia Memorial Research and Medical Center, Cabanatuan City, Philippines*

<sup>2</sup>*Department of Urology, East Avenue Medical Center, Quezon City, Philippines*

Presented here is a cases of a 12-year old female patient who was ran over by a reaper. After a comprehensive evaluation, she was advised to undergo transvesical subtrigonal buccal mucosa graft inlay for her almost completely obliterated bladder neck contracture. Such a procedure proved to be a viable option for the patient's bladder neck reconstruction.

**Key words:** Bladder neck contracture, urethral stricture, transvesical subtrigonal buccal mucosa graft

### Introduction

The true incidence of urethral strictures is unknown but some authors<sup>1,2</sup> put it at 4-20%. In the Philippines, there is no national database that keeps track of the number of strictures in the country, but a paper presented by Galut M., Abalajon M, et al described 547 strictures from 2020-2023.<sup>3</sup> Of these, only 11 were strictures in females. The causes of urethral strictures in women have been a topic of discussion for a considerable period.<sup>2</sup> Pelvic fracture resulting from blunt trauma to the lower abdomen can lead to posterior urethral disruption in males, which has been observed in male patients who were car passengers or fell from a height. While such injuries in males have been reported previously, they are considered to be rare in females.<sup>4</sup>

There are various treatment options available for urethral strictures, from conservative therapy to definitive procedures. However, studies<sup>5</sup> have shown that conservative techniques such as urethral dilation have a low success rate overall. Male urethral strictures are commonly treated with urethrotomy, with success rates for the first or subsequent urethrotomy were no higher than 9% in this series. With longer follow-ups, most of the patients in this series are expected to fail, and the expected long-term success rate from any urethrotomy approach is 0%.<sup>6</sup> On the other hand, augmented urethroplasty, which involves the use of flaps or grafts, has been established as the most effective and reliable definitive therapy for urethral strictures.<sup>7</sup>

The authors of this report aimed to present a case involving a 12-year-old female patient who

underwent a transvesical subtrigonal buccal mucosa graft inlay to repair an almost completely obliterated bladder neck. As to the authors' knowledge, this is the first reported case in the Philippines to utilize this technique.

### The Case

This is a case of a 12-year-old female who came in to the emergency room department 7 hours post-injury, after being run over by a reaper (truck). She arrived at the emergency room tachycardic and tachypneic. Physical examination revealed a flat, non-distended, soft, and non-tender abdomen but there was note of blood per meatus. Internal Examination (I.E.) revealed an anterior vaginal laceration 2 cm from the introitus. A pelvic x-ray revealed pelvic diastasis with an inferior rami fracture, left. A cystogram revealed extravasation of dye from the bladder to the vagina (Figure 1). Catheter insertion was done, which drained 200cc of clear urine output. There were no surgical plans, orthopedic-wise. With the patient's improved condition, she was sent home with an indwelling catheter which was replaced every two weeks. One-month post-catheterization, the previously noted urethrovaginal fistula on IE has healed. Unfortunately, the patient was lost to follow-up until one month prior to admission when she presented with acute urinary retention at the emergency room. An indwelling catheter was inserted with noted resistance 2 cm from the urethral meatus and the patient was directed to the OR for an emergency suprapubic cystostomy. Initial output was 800cc of urine. A repeat cystogram was done, revealing a completely obliterated bladder neck (Figure 2). Hence, the patient was scheduled for an elective urethral stricture repair.

### Conduct of Operation

After placing the patient in a lithotomy position, urethroscopy was performed where there was note of a 95% obliterated urethral lumen, 3cm from the meatus (Figure 3). Antegrade flexible cystoscopy through the suprapubic tract was performed, confirming the findings of an almost completely obliterated bladder neck.

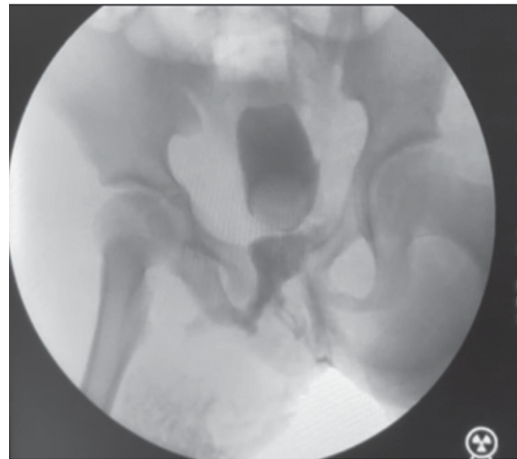

Figure 1. A cystogram showing extravasation of dye from the bladder to the vagina.

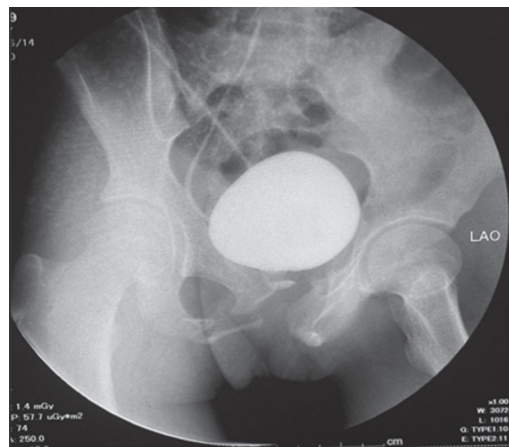


Figure 2. A cystogram revealing a completely obliterated bladder neck.

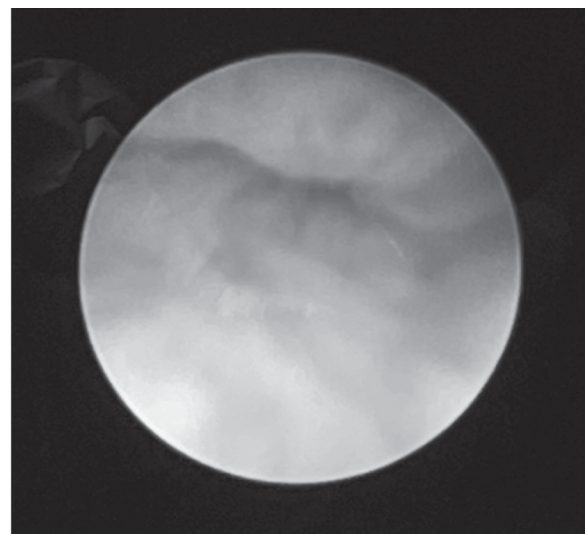
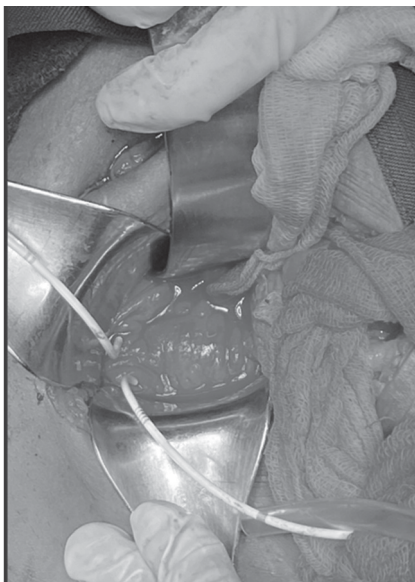

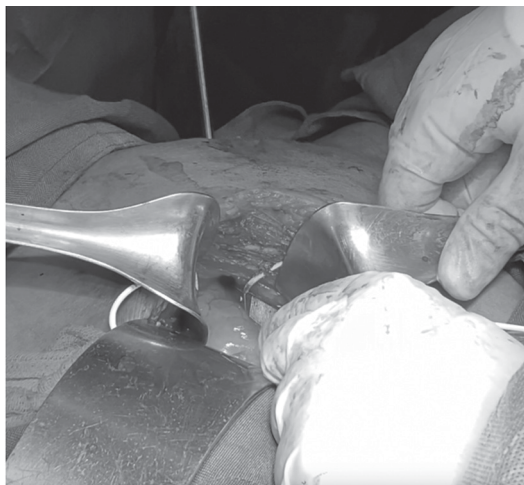Figure 3. A 95% obliterated urethral lumen was noted 3cm from the meatus.

An infraumbilical incision was made down to the retropubic area, exposing the bladder. The bladder was incised vertically along its anterior wall. Upon opening the bladder, both ureteral orifices were identified and cannulated with open-ended stents (Figure 4). A Fr16 Van Buren dilator wash then inserted into the meatus up to the level of the bladder neck. Under direct vision, mucosal incisions were made at the bladder neck from the 4 to 8 o' clock positions (Figure 5).

Using standard technique, a 2 cm x 1 cm mucosal graft was harvested from the buccal cavity

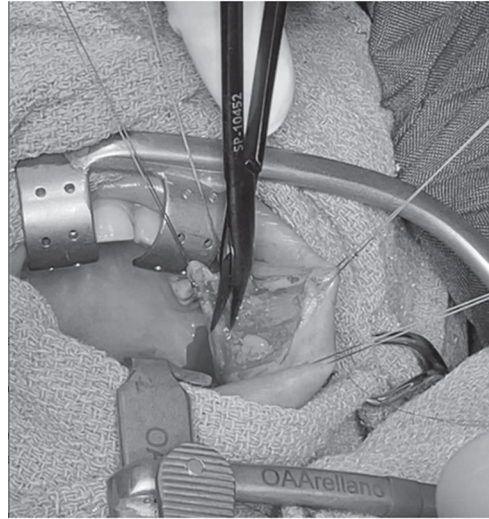


**Figure 4.** Urethral orifices cannulated with open-ended stents.



**Figure 5.** Mucosal incisions at the bladder neck from the 4 to 8 o'clock positions.

(Figure 6). The buccal mucosa graft was then spread-fixed and quilted to the denuded subtrigonal area with placement of Vicryl 4-0 sutures at the 4 to 8 o'clock positions (Figure 7).



**Figure 6.** A 2 cm x 1 cm mucosal graft was harvested from the buccal cavity.



**Figure 7.** Vicryl 4-0 sutures were placed at the 4 to 8' o'clock positions.

A Fr14 urethral catheter was inserted and a Fr16 suprapubic tube was replaced. The bladder was irrigated with sterile normal saline prior to closure. Cystorrhaphy was performed using a 2-layer technique, with Vicryl 4-0 for the mucosal layer and 2-0 for the seromuscular layer. A leak test was done by instilling 200cc of sterile water, and a Penrose drain was placed for drainage. Hemostasis was ensured before the procedure was completed.

The patient was discharged on the 3rd postoperative day. The urethral catheter was removed after 4 weeks, and the suprapubic tube was removed two weeks thereafter.

## **Discussion**

In men, blunt trauma to the lower abdomen with pelvic fracture may result in posterior urethral disruption, while in women, urethral and vaginal injury is less common. Urethral injury caused by pelvic ring disruption is usually observed in cases of rotationally unstable injuries, especially lateral compression injuries.<sup>8</sup>

Antoci and Schiff reported 125 female and 109 male patients with pelvic fracture, which included 11 girls and 15 boys below the age of 16. Out of these, 23 males experienced a ruptured urethra, while no cases of female urethral injury were reported.<sup>2</sup> In the literature, most urethral strictures are caused by iatrogenic injury, which is mostly attributed to traumatic instrumentation or urethral catheterization.<sup>4</sup> The same is true in the Philippines wherein the report by Galut and Abalajon, et al noted that 36.25% of urethral strictures resulted from iatrogenic injury.<sup>3</sup>

The incidence of female urethral strictures is much less common compared to that of males. Female pelvic fracture urethral injuries are rare with a worldwide incidence of 0.15%.<sup>9</sup> The treatment options for female urethral stricture (FUS) include endoscopic procedures or open urethral reconstruction.<sup>10</sup> While endoscopic treatment is less invasive, open urethral reconstruction is a more complex and invasive procedure. Nevertheless, open urethral reconstruction has a higher success rate.<sup>11</sup>

Migliari, et al conducted a study in which they performed urethral reconstruction using a dorsal buccal mucosa graft on three women between the ages of 45 and 65 who were suffering from urethral stricture disease. The results of the study showed that this approach, combined with buccal mucosa graft reconstruction, provided sufficient urethra in females, thereby reducing the risk of incontinence and fistula. Additionally, there was no residual urine, and the cosmetic outcomes were satisfactory.<sup>12</sup>

A systematic review by Osman, et al described 32 patients reported across seven studies, with buccal mucosa being used almost as frequently as lingual mucosa. The average success rate for buccal mucosa grafts was 94%, which was higher than the success rate for vaginal flaps (91%) and vaginal grafts (80%).<sup>7</sup> Richard, et al retrospectively reviewed charts of all female patients who underwent dorsal onlay oral (buccal or lingual) mucosa urethroplasty for urethral stricture between 2011 and 2020 showed a clinical success rate of 94.7% at 1-3 months and 90.9% at one year.<sup>11</sup> Joshi published a paper on a double-faced buccal graft inlay for near obliterative female urethral strictures and reported a good success rate.<sup>13</sup>

The problem with all of the above references, is that all of them dealt with strictures located in the mid to distal urethra. Performing a buccal graft inlay or onlay in the mid to distal urethra is relatively easy to perform but the patient in this case report had a stricture at the bladder neck where graft placement via a perineal approach would prove to be very difficult, if not impossible. In the past, female patients with strictures in the bladder neck either underwent repeated internal urethrotomies or urinary diversions such as a Mitrofanoff catheterizable channel. Flynn, et al, 2019 reported a novel technique wherein a buccal mucosal graft was placed as a subtrigonal inlay BMG in a 70-year-old male for treatment of refractory BNC. They were able to perform the technique using a transvesical approach with the aid of Da Vinci robot. There was no evidence of obstruction and recurrence on follow-up.<sup>14</sup> Using the principles described by Flynn, et al the authors were able to reproduce the same steps for this patient albeit an open approach.

## **Conclusion**

There are various treatment options available for the management of female urethral stricture, including conservative management with dilatation, endoscopic treatment, or open repair with different tissue flaps or grafts. But in cases where the location of the stricture is at the bladder neck, a subtrigonal buccal mucosal graft inlay might prove to be a very viable option for bladder neck reconstruction. This

is especially useful if the patient is not amenable to urinary diversion using bowel segments.

## References

1. Malde S, Solomon E, Spilotros M, Mukhtar B, Pakzad M, Hamid R, Ockrim J & Greenwell T. Female bladder outlet obstruction: Common symptoms masking an uncommon cause. *Lower Urinary Tract Symptoms* 2019; 11(1): 72–7. <https://doi.org/10.1111/luts.12196>
2. Antoci JP, Schiff M Jr. Bladder and urethral injuries in patients with pelvic fractures. *J Urol* 1982; 128: 25–6.
3. Galut MK & Abalajon MJ. Occurrence of Anterior Urethral Strictures Based on the 2020 LSE Anterior Urethral Stricture Classification System: A Descriptive Study. *Phil J Urol Suppl* 2020. <https://www.puaweb.org/wp-content/uploads/2022/01/PJU-Supplement-2020.pdf>
4. Latini JM, McAninch JW, Brandes SB, Chung JY & Rosenstein D. SIU/ICUD consultation on urethral strictures: Epidemiology, etiology, anatomy and nomenclature of urethral stenoses, strictures and pelvic fracture urethral disruption injuries. *Urology* 2014; 83(3): S1–7. doi:10.1016/j.urology.2013.09.009
5. Chua KJ, Mikhail M, Patel HV, Tabakin AL, Doppalapudi SK, Sterling J & Tunuguntla HS. Treatment of urethral stricture disease in women: Nonsystematic review of surgical techniques and intraoperative considerations. *Res Rep Urol* 2021; 13: 381-406. <https://doi.org/10.2147/RRU.S282651>
6. Santucci R & Eisenberg L. Urethrotomy has a much lower success rate than previously reported. *J Urol* 2010; 183(5): 1859–62. doi:10.1016/j.juro.2010.01.020
7. Osman NI, Mangera A & Chapple CR. A systematic review of surgical techniques used in the treatment of female urethral stricture. *Eur Urol* 2013; 64(6): 965–73. doi:10.1016/j.eururo.2013.07.038
8. Mundy AR & Andrich DE. Urethral trauma. Part I: introduction, history, anatomy, pathology, assessment and emergency management. *BJU Int* 2011; 108(3): 310–27. <https://doi.org/10.1111/j.1464-410X.2011.10339.x>
9. Bjurlin MA, Fantus RJ, Mellett MM & Goble SM. Genitourinary injuries in pelvic fracture morbidity and mortality using the National Trauma Data Bank. *J Trauma: Inj Infect Crit Care* 2009; 67(5): 1033–9. doi:10.1097/ta.0b013e3181bb8d6
10. Mathur R, Aggarwal G, Satsangi B, Khan F & Odiya S. Comprehensive analysis of etiology on the prognosis of urethral strictures. *Int Braz J Urol* 2011; 37(3): 362–70. <https://doi.org/10.1590/s1677-55382011000300010>
11. Richard C, Peyronnet B, Drain A, et al. Dorsal onlay oral mucosa graft urethroplasty for female urethral stricture, *Urology*. <https://doi.org/10.1016/j.urology.2021.09.001>.
12. Migliari R, Leone P, Berdondini E, De Angelis M, Barbagli G & Palminteri E. Dorsal buccal mucosa graft urethroplasty for female urethral strictures. *J Urol* 2006; 176(4): 1473–6. doi:10.1016/j.juro.2006.06.043
13. Joshi PM, Kulkarni SB. A new technique of double-face buccal graft urethroplasty for female urethral strictures. *Turk J Urol* 2019 Nov 29; 46(2):165-8. doi: 10.5152/tud.2019.19228.
14. Avallone MA, Quach A, Warncke J, Nikolavsky D & Flynn BJ. Robotic-assisted laparoscopic subtrigonal inlay of buccal mucosal graft for treatment of refractory bladder neck contracture. *Urology* 2019; 130: 209. <https://doi.org/10.1016/j.urology.2019.02.048>