

## Microsurgical Vasectomy Reversal in the Philippines – A Single Surgeon Experience

Ethan Victor Mallari, MD and Dennis G. Lusaya, MD, FPUA

*Section of Urology, University of Santo Tomas Hospital*

**Introduction:** Vasectomy is a simple and reliable method of permanent contraception in men causing obstructive azoospermia. As many as 50 million men worldwide have relied on vasectomy for family planning. However, it is estimated that around 6% of these men who underwent vasectomy will ultimately seek vasectomy reversal for various reasons.

Vasectomy reversal is the most cost effective option for couples desiring children after vasectomy and is the most challenging microsurgical procedures.

This study presents local experience, outcomes and complications of microsurgical reconstruction of the male ductal system in the Philippines setting.

**Methods:** This is a retrospective study of 157 post-vasectomy patients who underwent microsurgical vasectomy reversal by a single surgeon from January 2001 to March 2024. Outcomes such as patency and pregnancy rates were documented and analyzed.

**Results:** One hundred and fifty seven (157) underwent microsurgical vasectomy reversal. One hundred five (105) patients underwent bilateral microsurgical vasovasostomy. Forty eight (48) patients underwent combined microsurgical vasovasostomy and vasoepididymostomy. Three patients underwent bilateral vasoepididymostomy and one crossed microsurgical vasoepididymostomy (left to right). Four patients had no child, 87 patients had 1 child, 34 patients had 2 children, 29 had 3 children and 3 patients had 4 children prior to vasectomy. Age of wife was between 20 to 32 years old. Mean interval from vasectomy was 9 years. Vas deferens was patent in 120 (76%) of patients. Clinical pregnancy with successful delivery was achieved in 99 (63%) patients. There were only three who had postoperative hematoma (0.02%) and one developed surgical site infection (0.001%).

**Conclusion:** Microsurgical vasectomy reversal is an excellent option in men post vasectomy to achieve natural clinical pregnancy with minimal complications. The study confirms the effectiveness of male infertility microsurgery for vasectomized men who wish to father children.

**Key words:** Microsurgical vasectomy reversal, vasectomy, vasoepididymostomy

### Introduction

Vasectomy is globally recognized as a permanent form of male contraception, commonly used for family planning. Nonetheless, approximately 6% of men later opt to reverse the procedure, often due to changes in personal circumstances or specific

medical considerations. For couples aiming to have children post-vasectomy, reversing the surgery is considered the most cost-effective approach. Despite being one of the more challenging microsurgical procedures, especially in areas where trained microsurgeons are limited, vasectomy reversal is critical. In the Philippines, data regarding

the outcomes of this procedure is lacking, which this study intends to address by documenting experiences with microsurgical vasectomy reversals within the local context. In addition, other Asian countries where fertility treatments are becoming increasingly common, vasectomy reversals are gaining attention as an option for couples wishing to restore fertility. However, detailed regional statistics are sparse.

Obstructive azoospermia is defined as the absence of spermatozoa in the ejaculate despite normal spermatogenesis.<sup>1</sup> It is a common urologic condition and accounts for 6 to 13% of patients with fertility problems. Vasectomy is an easy and reliable method of permanent contraception causing obstructive azoospermia. As many as 50 million men worldwide have relied on vasectomy for family planning.<sup>2</sup> However, It is estimated that around 6% of these men who underwent vasectomy will ultimately seek vasectomy reversal for various reasons.<sup>2</sup> Indications for a vasectomy reversal include desire to have more children in case of remarriage or after death of a child, treatment of post vasectomy pain or treatment of obstructive azoospermia due to iatrogenic injury.<sup>3</sup>

In the modern era of assisted reproductive technology, infertile male patients with obstructive azoospermia (OA) have 2 options: vasal repair or testicular sperm extraction with intracytoplasmic sperm injection (ICSI). Vasal repair, either vasovasostomy (VV) and vasoepididymostomy (VE), is the only option that leads to natural pregnancy. Microsurgical vasovasostomy and vaso-epididymostomy are techniques that have undergone numerous advances during the last centuries, which includes use of microsurgical equipment and principles to construct a meticulous anastomosis.<sup>3</sup> Vasal repair may obviate the need for ICSI and thereby eliminate the risk and costs associated with assisted reproductive techniques.<sup>1</sup> Cost analysis reveals that vasectomy reversal is less expensive than ICSI.<sup>4</sup> ICSI also subjects the spouse to risk such as ovarian hyperstimulation syndrome with multiple gestation rates of 30%.<sup>1</sup> This carry risks to the mother and children such as prematurity and low birth weight. Advances in surgical techniques have improved outcomes of microsurgical vasal repair. There are studies demonstrating acceptable patency and

pregnancy rates of vasovasostomy without optical magnification and improved success rates with optical loupes.<sup>5</sup> However, modern microsurgical techniques remain the gold standard with which all other methods of vasectomy reversal are compared.<sup>5</sup> Little data on long-term outcomes for vasectomy reversal exist.<sup>3</sup> Therefore, the objective of this study was to evaluate the outcomes and complications of microsurgical reconstruction of the male ductal system in the Philippines setting.

## **Methods**

### **Patients**

This is a retrospective study of 157 post-vasectomy patients who underwent Microsurgical vasectomy reversal from 2001–2024. Complete history, prior inguino- scrotal surgery, age of female partner, physical examination, duration of vasectomy, presence of varicocele, vasal patency rate, clinical pregnancy rate and post vasectomy complications were recorded. Preoperative semen analysis was also done. If patient had either one of the following: has not fathered a child, a small testis, history of abnormal semen analysis or impaired sexual function, serum follicle-stimulating hormone (FSH), luteinizing hormone (LH) and total testosterone levels were requested.

The criteria for inclusion in the study were a minimum of 1 month and 6 months of follow-up with semen analysis performed according to World Health Organization methods. Patients were excluded if they did not provide a semen analysis.

### **Inclusion Criteria:**

- o Male patients who underwent vasectomy reversal surgery performed by the single surgeon between January 2001 and March 2024.
- o Patients who have adequate medical records, including operative reports, follow-up visits, and documented semen analysis results.
- o Patients with at least one documented follow-up visit after surgery to assess outcomes such as patency and complications.

Exclusion Criteria:

- o Patients whose medical records lack sufficient follow-up data to assess outcomes.
- o Patients with incomplete documentation regarding their vasectomy reversal surgery or pre-operative vasectomy history.
- o Patients who had secondary infertility factors that could impact outcomes (e.g., testicular trauma, infections unrelated to the vasectomy).

**Surgery and Intervention**

Patients underwent microsurgical vasectomy reversal. A vertical incision was done in each scrotum. A healthy portion of the vas deferens was isolated about 4 to 5 mm away from the vasectomy site. Meticulous dissection with liberal use of bipolar micro-coagulator for bleeding was performed. A Microspike™ approximator clamp was used to hold and stabilize the vas deferens and complete transection of the vas was done at a 90-degree perpendicular cut angle. Fluid was squeezed out from testicular portion of the vas deferens and examined for spermatozoa using light microscope at 40x magnification. (Figure 1). Abdominal portion of the vas was flushed with 5 to 10 mL saline to confirm patency. Modified 3-layer anastomosis was done in all patients. Using microdot technique, 6 interrupted sutures were placed in each layer: mucosal (10-0 monofilament

nylon), muscular (9-0 monofilament nylon), and adventitial (8-0 monofilament nylon). Tunica vaginalis, dartos and skin were closed with continuous 4-0 V the vicryl suture.

Vasoepididymostomy is performed if the fluid on the testicular end of the vas is devoid of sperms, dry and toothpaste like. The authors' preference is the two suture technique known as the longitudinal intussusception vasoepididymostomy. In this technique, two double-armed 10-0 nylon sutures were used, and the needles were placed along the length of the tubule. A longitudinal incision is then made on the tubule and the fluid was examined for sperms under the microscope. Once confirmed, the needles were pulled through and passed through the corresponding location in the vas.

**Statistical Analysis**

*Descriptive Statistics*

Post Vasectomy (Obstructive Azoospermia) (N=157)

For patients who had no known surgery like vasectomy, have not fathered a child: azoospermia, with normal hormones, FSH, testosterone, normal volume alkaline pH semen and a palpable dilated epididymis, all patients with obstructive azoospermia had a bilateral testicular biopsy confirming normal spermatogenesis

A. Demographic data of patients by nationality

Nationality	No.
American	108
British	27
Canadian	6
Australian	12
New Zealand	2
Filipino	2
Norwegian	1
African (Bostwana)	1
Total	157

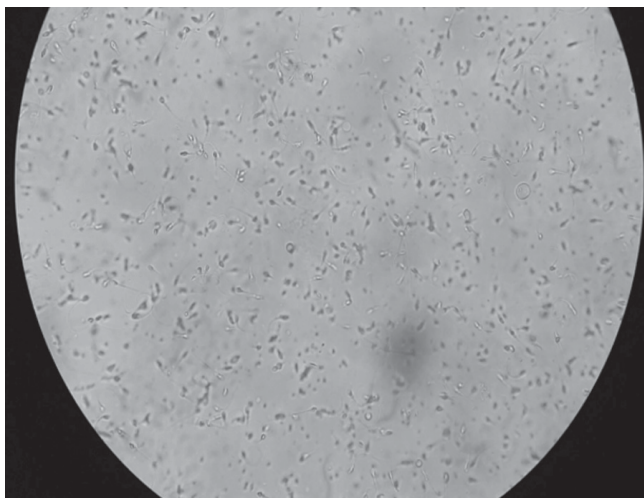


Figure 1. Intraoperative examination of vasal fluid (testicular end)

B. Baseline characteristic and summary of results

Number , n	
Male age, mean (SD)	58.2 (± 5.9)
Female age, mean (SD) years	29.5 (± 4.1)
Time since vasectomy, mean (SD) years	14.5 (± 5.3)
Operative time, mean (SD) minutes	210 (± 31)
Complications	3 (2%)
Overall Patency	120 (76%)
Pregnancy Rate	99 (63%)
Total Sperm Count, mean (SD) millions	55 (±10.3)

C. Number of children prior to vasectomy

None	4
1	87
2	34
3	29
4 or more	3
Total	157

D. Type of microsurgical vasectomy reversal

Type of Reversal	No.
Vasovasostomy (bilateral)	105
Vasovasostomy and Vasoepididymostomy	48
Vasoepididymostomy (bilateral)	3
Crossed Microsurgical Vasoepididymostomy (Left to Right)	1
Total	157

E. Duration of obstructive interval

No. of years post-vasectomy (known obstruction)	No.
0-5 yrs	5
5-10 yrs	78
10-15 yrs	45
15- 20 yrs	18
20 yrs or more	11
Total	157

F. Clinical outcome on the type of microsurgical reversal:

Type of Reversal	No.	Vasal Patency Rate (%)	Clinical Pregnancy Rate (%)
Vasovasostomy (bilateral)	105	85 (80%)	66 (63%)
Vasovas & Vasoepididymostomy	48	33 (68%)	32 (66%)
Vasoepididymostomy (bilateral)	3	2 (67%)	1 (33%)
Crossed Vaso epididymostomy	1	0	0
Total	157	120 (76%)	99 (63%)

G. Intraoperative examination of vasal fluid:

No. of years post- vasectomy	Intraop Sperms (+)	Intraop Sperms (-)
0-5	5	2
5-10	78	70
10-15	45	29
15- 20	18	5
20 yrs or more	11	0

## Preoperative Evaluation

A complete history and physical examination was performed prior to proceeding with surgical intervention. Attention should be paid to the duration of time since the vasectomy, any prior inguinal (hernia repair) or scrotal surgery, any post vasectomy complication, the age of the female partner, and any potential female factor that is contributing to infertility. Along with routine preoperative tests, a careful genital examination should be performed. The physical examination includes the size and volume of the testicles (measured with a Prader orchidometer), a palpable vasal defect, the presence of a sperm granuloma, and if possible, the length of the testicular vasal segment. In addition, determining the presence of a varicocele is important because a varicocelectomy can be performed alongside the vasal reconstruction in selected cases. Formal vasography rarely is necessary. In laboratory investigations, the measurement of the gonadotropin (FSH and LH) and testosterone levels should be considered for patients with small testis, a history of abnormal semen analysis, or impaired sexual function.

## Operative Steps

Anesthesia: Either General LMA or Regional Epidural (continuous) majority of the cases

Technical Description:

1. Placement of the Incision
2. Preparation of the Vas (Figure 2)
3. Decision or choice whether to perform vasovasostomy or vasoepididymostomy
4. Method of Anastomosis

For Vasovasostomy (Figures 3 & 4)

- Modified Microdot, 6 interrupted 10-0 monofilament nylon (mucosal)
- 6 interrupted 9-0 monofilament nylon (muscular)
- 6 interrupted 8-0 monofilament nylon (adventitial)

For Epididymovasostomy (Figures 5-6):

- Longitudinal or transverse Intussusception technique, End to side
- 10-0 double arm nylon suture (2)
- 8-10 interrupted 9-0 suture to secure vassal adventitia to tunica of the epididymis

Closure of Tunica Vaginalis, Dartos, and skin continuous 4-0 vicryl suture

## Patency and Pregnancy

One hundred and thirty-six (136) patients underwent microsurgical vasectomy reversal.



Figure 2. Modified microdot technique.

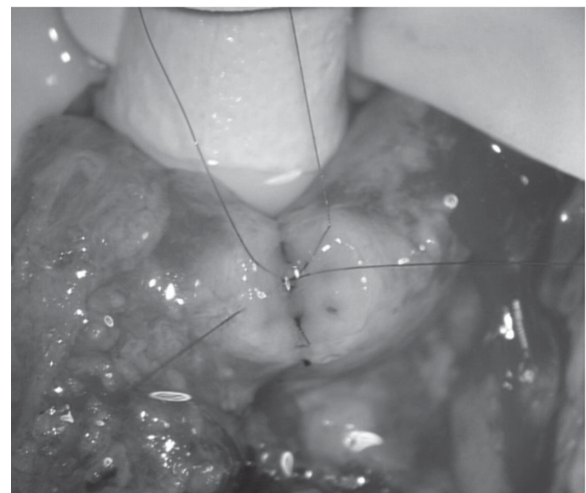
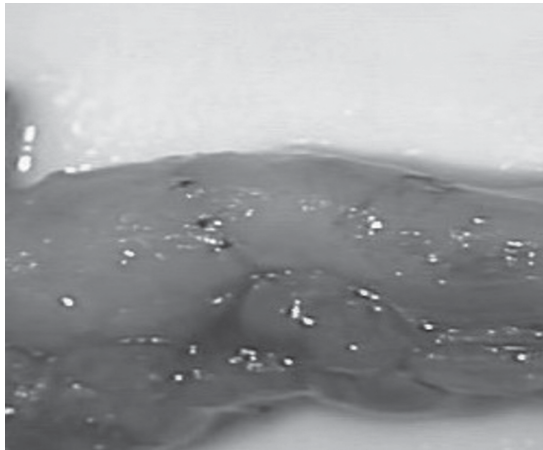
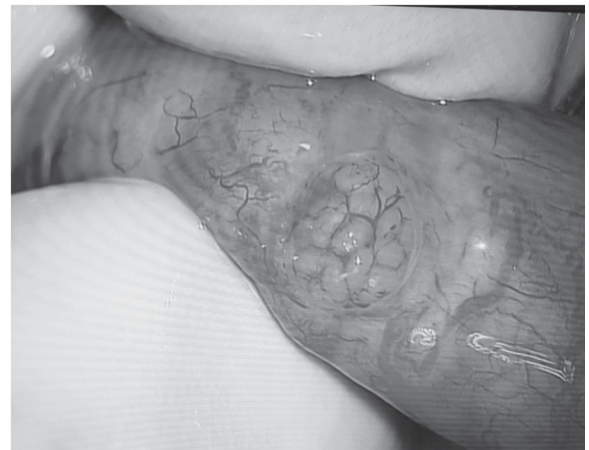

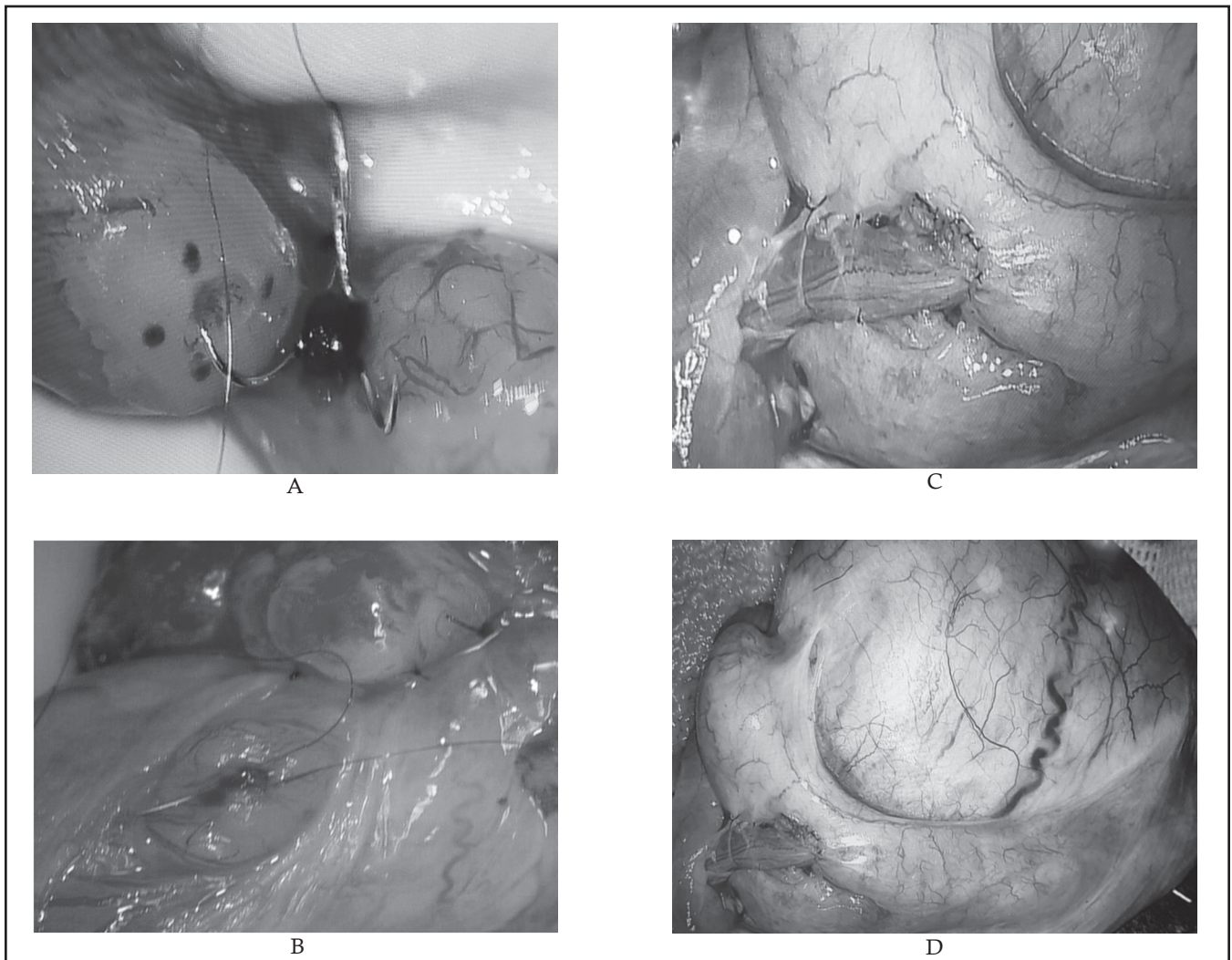
Figure 3. Vasovasostomy: Modified Microdot, 6 interrupted 10-0 monofilament nylon (mucosal)



**Figure 4.** Vasovasostomy



**Figure 5.** Preparation of Epididymis for Epididymovasostomy



**Figure 6.** Epididymovasostomy: Longitudinal or transverse Instussusception technique, End to side

Preoperative semen analysis and preoperative testicular biopsy were done in all patients.

Ninety-one (91) patients underwent bilateral microsurgical vasovasostomy. Eighty-two (82) patients underwent combined microsurgical vasovasostomy and vasoepididymostomy. Three (3) patients underwent bilateral vasoepididymostomy and one crossed microsurgical vasoepididymostomy (left to right). The Intraoperative microscopic fluid examination of the testicular vasal end in 42 patients showed no sperms hence vasoepididymostomy was performed. Four patients had no child, 66 patients had 1 child, 34 patients had 2 children, 29 had 3 children and 3 patients had 4 children prior to vasectomy. Age of wife was between 20 to 32 years old. Mean interval from vasectomy was 9 years. Vas deferens were patent in 103 (76%) of patients. Clinical pregnancy with successful delivery was achieved in 87 patients (64%). There were only three who had postoperative hematoma (2%) and one developed surgical site infection (0.7%).

## **Discussion**

Patency, which is defined as return of sperm to ejaculate, has been the primary outcome measure for vasovasostomy.<sup>5</sup> With this criterion, results using microsurgical techniques are consistently superior with non-microsurgical anastomotic technique.<sup>5</sup> Patency rate is around 80% in most case series.<sup>5</sup> In the current study, the authors found that microsurgical vasovasostomy results in return of sperm in 76% of men following microsurgical vasovasostomy and spontaneous pregnancy rate of 63%. Microsurgical vasovasostomy is the preferred technique for vasectomy reversal for most Urologists. If there is no sperm granuloma and the vas is absolutely dry and spermless after multiple samples have been examined, vasoepididymostomy is indicated. It is performed when testis biopsy reveals complete spermatogenesis and scrotal exploration reveals the absence of sperm in the vasal lumen without vasal or ejaculatory duct obstruction.<sup>11</sup> Microsurgical vasoepididymostomy is the most technically demanding procedure in all microsurgeries and should be attempted only by microsurgeons who perform the procedure frequently. As the obstructive interval increases, the likelihood of needing vasoepididymostomy

increases in several studies. According to Mui, et al, the rate of vasoepididymostomy increased linearly with vasectomy intervals of 1.22 years at 3% per year but plateaued at 72% with vasectomy intervals of 24-38 years. The sperm counts were maintained with increasing time after the vasectomy, but the motile sperm counts decreased significantly.<sup>12</sup> It is performed by accurate approximation of the vasal mucosa to that of a single epididymal tubule, resulting in marked improvement in the patency and pregnancy rates.

Modified 3-layer vasovasostomy with microdot technique was used to provide precise mucosal approximation of vasal layers and leak proof anastomosis. Goldstein et al described the microdot technique in 1998 at Weill Cornell Medical College.<sup>6</sup> This technique allows vas lumen to be brought together more precisely. Precise suture placement mapping prevents dog-ears, and subsequent leaks can be avoided. Total of six microdots are placed on cut ends of vas. The first mucosal layer is placed utilizing the microdots and 10-0 monofilament suture. Use of double-armed suture prevents back walling of vas lumen. Second layer approximates the deep muscularis layer with a 9-0 monofilament suture. Then the third layer closes the adventitial layer in a watertight fashion with a 8-0 monofilament suture. All sutures are placed in an interrupted fashion.<sup>6</sup> The principles of vasovasostomy include accurate and leak-proof mucosal approximation, a tension-free, healthy tissue with good blood supply and atraumatic anastomosis technique.<sup>5</sup> These principles, when followed, maximize the chance of success. Although assisted reproductive technologies have significantly impacted the treatment of male infertility, microsurgical reconstruction remains the most successful and cost-effective method of treatment in patients with obstructive azoospermia. The success of it in establishing pregnancy makes this procedure a treatment of choice in men wishing to father children after vasectomy.

The outcome of vasectomy reversal is influenced by several factors such as duration of obstruction. A large study conducted by the Vasovasostomy Study Group observed that both patency and pregnancy rates after vasovasostomy decreased as the time since vasectomy increased.<sup>2</sup> Current data are consistent with previous studies demonstrating

that patency rate is inversely related to the duration of vasal obstruction. Vasectomy has adverse effects on reproductive system and is time-dependent.<sup>5</sup> Studies demonstrate role of immunologic factor related to vasectomy that may affect sperm production and activity. The inverse relationship between success rates and interval of obstruction may reflect progressive testicular damage.<sup>2</sup>

Patients are generally operated as outpatient and discharged postoperatively. After microscopic vasectomy reversal, instruction to place ice pack over the scrotum for 48 hours to wear scrotal support for 4 weeks, light activity starting 3 days postoperatively and avoidance of sexual activity, strenuous activity for 4 to 6 weeks are advised.<sup>3</sup> Oral with analgesic and anti-inflammatory agents are given for 7 days. Semen analyses should be obtained approximately every 2 months until sperm concentration and motility return to normal or until pregnancy occurs.<sup>2</sup> Follow up consist of clinic visits, phone calls, SMS and regular update on email.

In the age of in vitro fertilization or Intracytoplasmic sperm injection, patients now have a choice between surgical sperm retrieval coupled with IVF/ICSI versus vasectomy reversal. While surgery may be challenging, microsurgical vasectomy reversal results in excellent patency and pregnancy outcomes.

## Conclusion

Microsurgical reconstruction of the male ductal system is an excellent option in fertility in male with obstructive azoospermia to achieve clinical pregnancy post vasectomy with minimal complications. The study confirms the effectiveness of male infertility microsurgery for vasectomized men who wish to father children. Adherence to good microsurgical techniques will result in excellent outcomes for couples electing vasectomy reversal.

## References

1. Baker K, Sabanegh E. Obstructive azoospermia: reconstructive techniques and results. *Clinics* 2013; 68(S1): 61-73.
2. Yu Seob S, Sang D, Jong K. Preoperative factors influencing postoperative results after vasovasostomy. *World J Mens Health* 2012; 30(3): 177-82.
3. Herrel L, Hsiao W. Microsurgical vasovasostomy. *Asian J Androl* 2013; 15: 44-8; doi:10.1038/aja.2012.79
4. Pavlovich CP, Schlegel PN. Fertility options after vasectomy: A costeffectiveness analysis. *Fertil Steril* 1997; 67(1):133-41. [Http://Dx.Doi.Org/10.1016/S0015-0282\(97\)81870-5](http://Dx.Doi.Org/10.1016/S0015-0282(97)81870-5).
5. Bolduc S, Fischer MA, Deceuninck G, Thabet M. Factors predicting overall success: a review of 747 microsurgical vasovasostomies. *Can Urol Assoc J* 2007; 1 (4): 388-94.
6. Goldstein M, Li PS, Matthews GJ. Microsurgical vasovasostomy: the microdot technique of precision suture placement. *J Urol* 1998; 159: 188-90.
7. Schwarzer JU. Vasectomy reversal using a microsurgical three-layer technique: one surgeon's experience over 18 years with 1300 patients. *Int J Androl* 2012;35:706-13.
8. Schwarzer JU, Steinfatt H. Current status of vasectomy reversal. *Nat Rev Urol* 2013;10:195-205.
9. Smith JF, Walsh TJ. The aging male. In: Lue TF, editor; McAninch JA, Lue TF. (editors): *Smith and Tanagho General Urology*. 18th. Philadelphia: MGravHillCo; 2013; 722-40.
10. Turek PJ. Male reproductive physiology. In: Peters P, Wein AJ, Kavoussi L, Partin A, Partin A (editors): *Campbell-Walsh Urology*. 11th. Philadelphia: Elsevier Press; 2016.
11. Wein IJ, Kavoussi LR, Partin AW & Peters CA. *Campbell-Walsh Urology: 4-Volume Set 11th Edition*. 2015
12. Mui P, Perkins A, Burrows PJ, Marks SF, Turek PJ. The need for epididymovasostomy at vasectomy reversal plateaus in older vasectomies: a study of 1229 cases. *Andrology* 2014; 2: 25-9.
13. Fuchs ME, Anderson RE, Ostrowski KA, Brant WO, Fuchs EF. Pre-operative risk factors associated with need for vasoepididymostomy at the time of vasectomy reversal. *Andrology* 2016; 4: 160-2.
14. NEGHRIIP 2022. National Ethical Guidelines for Research Involving Human Participants. <https://ethics.healthresearch.ph/index.php/phocadownloads/category/4-neg>
15. Data Privacy Act of 2012. <https://privacy.gov.ph/data-privacy-act/#w4>